Case Report

Tuberculous Pericarditis

Suchato C, MD
email : chirotchana@bgh.co.th

Chirotchana Suchato, MD[1]
Rergchai Varatorn, MD[1]
Vitoon Pitiguagool, MD[2]
Paitoon Boonma, MD[3]

[1] Imaging Center, Bangkok Hospital, Bangkok Hospital Group, Bangkok, Thailand.
[2] Division of Cardiothoracic and Vascular Surgery, Bangkok Heart Hospital, Bangkok Hospital Group, Bangkok , Thailand.
[3] Infectious Clinic, Bangkok Hospital, Bangkok Hospital Group, Bangkok, Thailand.

Keywords:
Pericarditis, Tuberculous pericarditis

Tuberculous pericarditis, caused by Mycobacterium Tuberculosis, is found in approximately 1% of all autopsied cases of tuberculosis (TB) and in 1% to 2% of instances of pulmonary TB.[1] Pericardial involvement usually develops by the retrograde lymphatic spread of Mycobacterium Tuberculosis from peritrachial, peribronchial or mediastinal lymph nodes or by hematogenous spread from primary tuberculous infection.[2, 3] Tuberculous pericarditis presents clinically in 3 forms, consisting of pericardial effusion, constrictive pericarditis and a combination of effusion and constriction.[4]

Case Report

A 66-year-old woman presented with dyspnea, palpitations and inability to lay flat in bed since 2 months. The pertinent laboratory investigations included sputum examination which was negative. CA125 was positive. Gram stain showed no microorganism. Pleural fluid of AFB culture showed no Mycobacterium spp. isolated. Polymerase chain reaction (PCR) for TB showed negative for Mycobacterium Tuberculosis.

The Echocardiogram showed fluid collection in the pericardial sac. The electrocardiography (EKG) showed prolonged QT.

The CT chest (Figure 1) revealed 2.8 cm diameter, heterogeneously enhancing lesion at anteroinferior aspect of the pericardium. There was no extension into the heart chamber, multiple foci micro calcification at wall of pericardial were seen which was indicative of chronic granulomatous condition. Tuberculous pericarditis should be considered.

The ^{18}F-fluorodeoxyglucose positron emission tomography/computed tomography (^{18}FDG PET/CT) scan (Figure 2) showed increased metabolic activity at pericardium (standardized uptake value (SUV) = 3.8). There was also increased ^{18}FDG uptake at right axillary node (SUV = 1.2) (Figure 3).

The tuberculin skin test also showed positive result (Figure 4).

The MRI study of the heart with gadolinium (Figure 5) showed localized thick wall of pericardium with rim contrast enhancement. The inner wall of pericardium was thickening and irregular fine filling defects projected into the pericardial effusion which is compatible with chronic granulomatous pericarditis. This is a classical sign of tuberculous pericarditis.

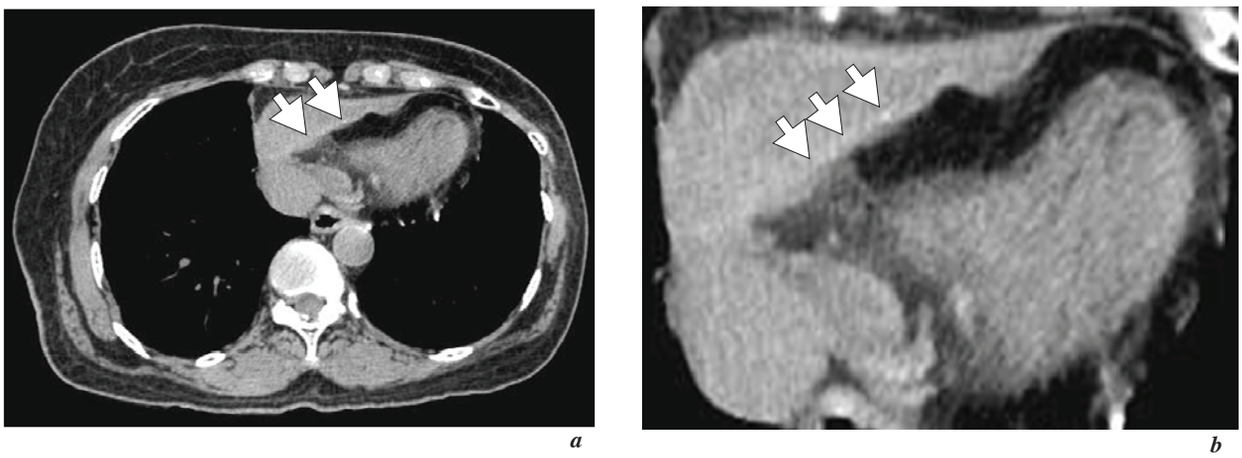

Figure 1 a-b: *CT Chest shows thick pericardium at anteroinferior border with multiple foci microcalcification at wall of pericardium. This indicats granulomatous condition. Tuberculous pericarditis should be considered.*

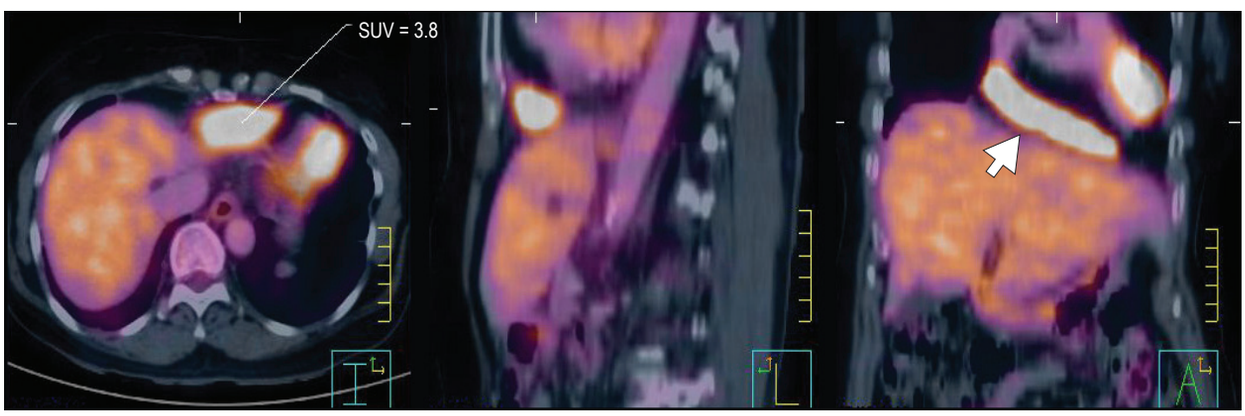

Figure 2: *The ^{18}FDG PET/CT scan shows increased metabolic activity activity at pericardium (SUV = 3.8).*

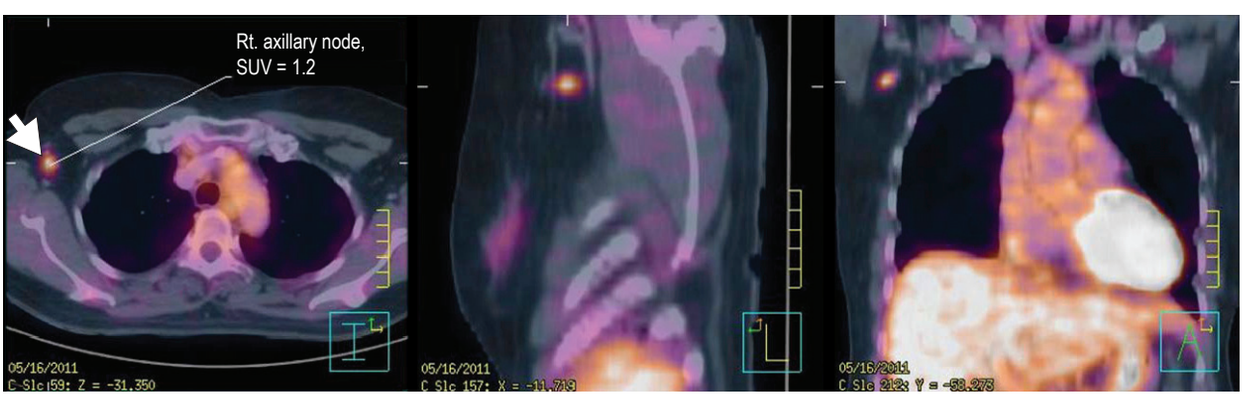

Figure 3: *The ^{18}FDG PET/CT scan shows increased ^{18}FDG uptake at right axillary node (SUV = 1.2).*

Figure 4: *The tuberculin skin test shows positive result.*

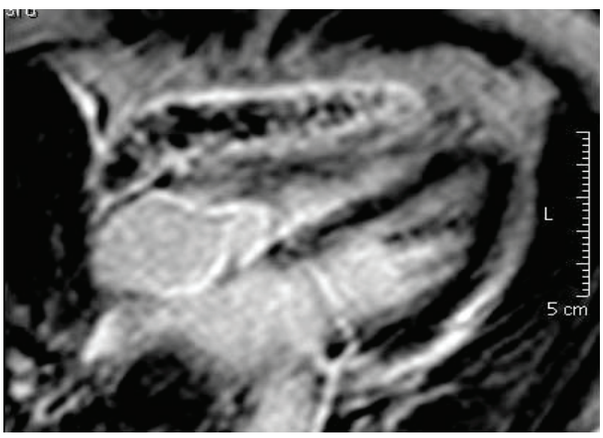

Figure 5: *The MRI study of the heart with gadolinium shows localized thick wall of pericardium with rim contrast enhancement. The inner wall of pericardium was thickening and irregular fine filling defects projected into the pericardial effusion which is compatible with chronic granulomatous pericarditis.*

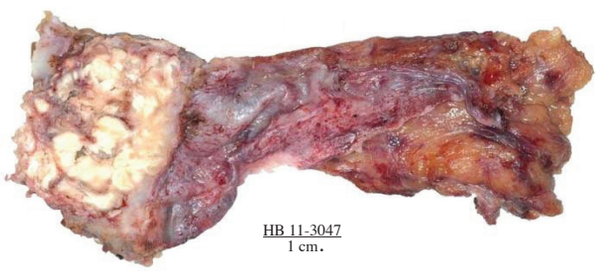

Figure 6: *The gross specimen consisted of a fibrocalcific mass size 3.5x3.5x1.8 cm. Cut section of the mass showed old and recent caseous material. The pericardium close to the mass was scarred and thick, up to 0.8 cm. The pericardium away from the mass was relatively normal.*

Discussion

Tuberculous pericarditis is responsible for approximately 4% of cases of acute pericarditis. It is a rare but life-threatening condition.[1] Tuberculosis (TB) is a serious problem in developing countries. The diagnosis is made by the identification of Mycobacterium Tuberculosis in the pericardial fluid or tissue and or the presence of caseous granulomas in the pericardium. PCR can identify DNA of Mycobacterium Tuberculosis from pericardial fluid: Pericardial biopsy provides a rapid and definite diagnosis.

Cardiac tamponade and constrictive pericarditis are two major lethal complications. In early stage patients with minimal pericardial effusion, pericardiocentesis with biopsy can be conducted to confirm the diagnosis. If cardiac tamponade develops, creation of a pericardial window should be done. If constrictive pericarditis presents, pericardiectomy is the treatment of choice.[4]

Conclusion

This case represented pericarditis identified by CT and MRI. The clue to diagnosing granular pericarditis was the thick wall of the pericardium with fine irregular border projecting into the pericardial effusion. Multiple microcalcification at the pericardium is a pathogenoic sign of chronic granulomatous disease.

References

1. Fowler NO. Tuberculous pericarditis: *JAMA* 1991;266: 99-103.
2. Spodick DH. Tuberculous pericarditis. *Arch Intern Med* 1956; 98:737-49.
3. Ortbais DW, Avioli LV. Tuberculous Pericarditis. *Arch Intern Med* 1977;139:231-4.
4. Mayosi MB, Burgess JL, Doubell FA. *Circulation* 2005; 122:3608-16.